Ischiofemoral Impingement and Hamstring Syndrome as Causes of Posterior Hip Pain

Where Do We Go Next?

Hal David Martin, DO*, Anthony Khoury, MS, Ricardo Schröder, PT, Ian James Palmer, PhD

KEYWORDS

• Ischiofemoral impingement • Hamstring syndrome • Posterior hip pain • Deep gluteal syndrome • Sciatic nerve entrapment • Ischial tunnel • Hamstring tear

KEY POINTS

- Independently, or in combination, deep gluteal syndrome (DGS) can be associated with distal etiologies, such as hamstrings syndrome and ischiofemoral impingement.
- Six key physical examination tests are used to diagnose DGS, hamstrings syndrome, and ischiofemoral impingement when posterior hip pain is a complaint.
- Nonoperative and operative treatment planning is based on the differential diagnosis of posterior hip pain and the contributing pathoanatomy.

Recent advances in understanding the hip joint anatomy and biomechanics have contributed to the improvement of diagnosis and treatment decisions for deep gluteal syndrome (DGS).[1–5] Independently, or in combination, DGS can be associated with distal etiologies, such as hamstrings syndrome and ischiofemoral impingement (IFI). The presence of a scarred sciatic nerve (SN) to the hamstrings tendon, in cases of hamstrings syndrome, and SN impingement between the ischium and the lesser trochanter are isolated causes of posterior hip pain that can be distinguished between intrapelvic or extrapelvic SN entrapment.[3,6–10]

IFI and hamstrings syndrome are 2 sources of posterior hip pain that can simulate symptoms of DGS. These 2 dynamic pathologic conditions are associated with physical activity, and the coexistence of both conditions cannot be excluded.[3,10] To evaluate the etiology of posterior hip pain, it is necessary to understand, correlate,

Disclosure: The authors have nothing to disclose.
Hip Preservation Center, Baylor University Medical Center, 3900 Junius Street, Suite 705, Dallas, TX 75246, USA
* Corresponding author.
E-mail address: haldavidmartin@yahoo.com

Clin Sports Med 35 (2016) 469–486
http://dx.doi.org/10.1016/j.csm.2016.02.010 sportsmed.theclinics.com
0278-5919/16/$ – see front matter © 2016 Elsevier Inc. All rights reserved.

Downloaded from ClinicalKey.com at Ohio State University Libraries August 26, 2016.
For personal use only. No other uses without permission. Copyright ©2016. Elsevier Inc. All rights reserved.

and assess the interaction among the osseous, capsulolabral, musculotendinous, neurovascular, and kinematic levels. The combination of a comprehensive history and physical examination with imaging and ancillary testing are critical to diagnose DGS precisely.[3,5,10,11]

Johnson and Rochester[12] first described the surgical treatment for IFI in 1977, when noticing a narrowing ischiofemoral space associated with posterior hip pain after a total hip implant. The case was successfully treated with resection of the lesser trochanter. More recently, Hatem and colleagues,[4] in a 2-year outcome study, showed an improvement of the symptoms after partial lesser trochanterplasty in subjects diagnosed with IFI. Surgical procedures to treat chronic hamstrings tears and avulsions have reported positive outcomes in comparison with nonoperative treatment. Positive outcomes are also confirmed for surgical procedures to release scar tissue between the hamstrings tendons and SN.[2,8,13,14]

The goal of this article was demonstrate how to recognize and diagnose the distal causes of DGS. Readers will be able to distinguish independent IFI or hamstrings syndrome, which can exist with or without SN impingement.

ANATOMY AND BIOMECHANICS

The anatomic and biomechanical relationship of the SN to the proximal hamstrings insertion in the deep gluteal space is critical to diagnosis the distal causes of DGS. After exiting the pelvis anterior to the piriformis muscle, the SN runs posteriorly to the obturator/gemelli and quadratus femoris muscle, located at the most lateral aspect of the ischial tuberosity. The SN also maintains an intimate relationship with the hamstrings origin.[10,15] Within the ischiofemoral space, the SN shares the same spatial location with the lesser trochanter, which is separated from the SN by the quadratus femoris muscle.[10,15] The proximal insertion of the semimembranosus muscle at the lateral aspect of the ischium is another structure that shares the same anatomic spatial location within the ischiofemoral space. Distal to the ischium (7 cm from the ischial tuberosity), the first branch of the SN emerges adjacent to the long head of the biceps femoris, which can also contribute to SN entrapment as it courses to the lower extremity[9,15] (**Fig. 1**).

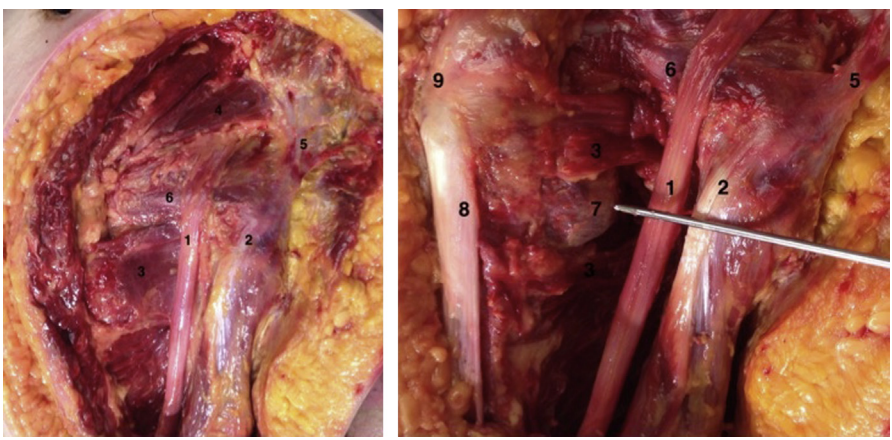

Fig. 1. Anatomy of the deep gluteal space. (1) SN; (2) conjoint tendon of semitendinosus and biceps femoris; (3) quadratus femoris muscle; (4) piriformis muscle; (5) sacrotuberous ligament; (6) obturator internus muscle; (7) lesser trochanter; (8) tensor fascia latae; (9) greater trochanter.

Downloaded from ClinicalKey.com at Ohio State University Libraries August 26, 2016.
For personal use only. No other uses without permission. Copyright ©2016. Elsevier Inc. All rights reserved.

Located distally and medially to the sciatic notch, the sacrotuberous and sacrospinous ligaments have an important function in contributing to the symptoms of DGS and pudendal nerve entrapment.[16,17] The sacrotuberous ligament has extensions to the semitendinosus and biceps femoris tendon on the origin and share the same fascial insertion at the ischium. Tenderness or injuries of the sacrotuberous ligaments could be present in cases of chronic semitendinosus injuries and pudendal nerve entrapment.[18–20]

Isolated lesions in the proximal insertion of the hamstrings tendons can reproduce symptoms associated with DGS. Chronic and repetitive tears or a single acute lesion can contribute to the development of hamstrings syndrome.[9] In addition to the nature of the injury, traumatic or chronic, it is important to be aware of gluteal sitting pain.[3] Subjects with proximal hamstrings injuries may experience functional incapacity and pain at the ischium or lateral to the ischium with sitting, stretching, and during exercises, which is caused by SN traction, compression, or irritation.[9]

The development of extra-articular impingement with hip pain and kinematic compensation has been associated to abnormalities of the proximal hip morphology and its relationship with the ischiofemoral space.[3,21–23] In a study performed by Gómez-Hoyos and colleagues,[21,22] the femoral version and lesser trochanter version were compared between individuals with surgical confirmation of IFI versus asymptomatic subjects. Lesser trochanter angle does not show difference between groups; the symptomatic group showed significantly increased femoral anteversion and lesser trochanteric version angle (**Fig. 2**). Lesser trochanteric version alone does not influence the ischiofemoral space (IFS), the lesser trochanteric version may have an influence in subjects with chronic hamstrings tears, as observed clinically by the lead author (H.D. Martin). Further studies need to confirm these anatomic variations.

Tears in the proximal insertion of the hamstrings and lesser trochanteric impingement are 2 conditions that may coexist and simulate distal symptoms of DGS. Patti and colleagues[6] first reported these conditions in a case study of IFI. Posteriorly, Torriani and colleagues[7] showed that 5 of 10 subjects had a presence of proximal hamstrings tears associated with IFI. More recently, Gómez-Hoyos and colleagues[3]

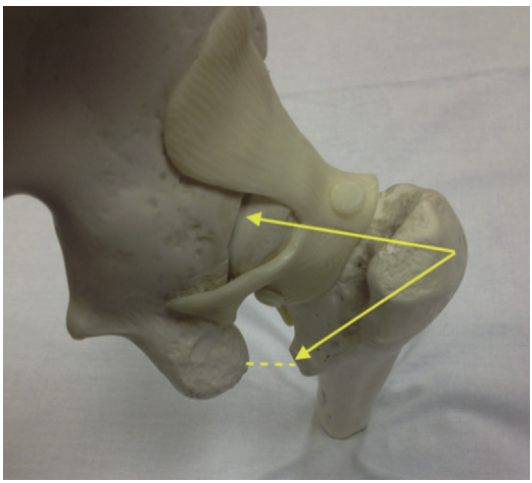

Fig. 2. Relationship of proximal femoral anatomy and the ischiofemoral space. (*Yellow arrows* represent the angle between the femoral version and lesser trochanteric version. *Dashed yellow* is the ischiofemoral space.)

Downloaded from ClinicalKey.com at Ohio State University Libraries August 26, 2016.
For personal use only. No other uses without permission. Copyright ©2016. Elsevier Inc. All rights reserved.

used 17 subjects with IFI to validate the specificity and sensitivity of the long stride walking and IFI test to diagnose IFI. The population of the study showed as associated symptoms sitting pain (88.2%) and radiating pain (11.7%), 2 signs that have been consistently associated with DGS.

For the anatomy of the peritrochanteric space, the SN biomechanics should be understood. Normal hip joint motion results in a direct influence on neural tissue stretching, compression, and position. During straight leg raise, hip flexion with the knee in extension, the SN experiences an average of increased strain of 26%. The nerve also experiences proximal excursion the average of 28 mm at 70° to 80° of hip flexion.[24,25] As demonstrated in animal studies, the nerve conduction is completely blocked with 12% of strain, presenting minimal recovery after 1 hour.[26,27] Khoury and colleagues[28] showed that altering hip position in the frontal plane, increasing the hip abduction, decreased the strain parameters of the SN an average of 83.65%. In the same study, the investigators observed a "wrap-around" phenomenon, when the nerve spins on its axis during hip flexion. The investigators observed that the loss of the capacity to "wrap around" due to scars and entrapments may contribute to an abnormal nerve kinematics. The abnormal pathoanatomy not only affects the nerve impingement but can also affect the epineurial direction of normal nerve biomechanics. Restoring the normal SN excursion parameters are dependent on correcting the impinging pathoanatomy.

HISTORY AND PHYSICAL EXAMINATION

The assessment of posterior hip pain requires a complete history, comprehensive physical examination, and a standardized radiographic exploration to diagnose posterior hip pain precisely.[10,11] To evaluate the functional level of the patient and measure the outcomes of the treatment addressed, each patient undergoes a self-administered evaluation (International Hip Outcome Score and Harris Hip Score) as a part of the standard workup for posterior hip pain.[29]

Hamstrings syndrome and IFI can be associated with symptoms of DGS. Patients with SN entrapment often have a history of trauma and symptoms of sit pain (inability to sit for >30 minutes), radicular pain of the lower back or hip, and paresthesias of the affected leg.[9] As previously cited, patients with hamstrings syndrome and IFI can present radicular pain, and the coexistence of these conditions should be considered.[29]

The differential diagnosis of posterior hip pain can be localized to proximal or distal regions. Those producing distal SN impingement have different complaints from those who exhibit pain with walking or sitting. An example of pain exacerbated by sitting can include driving; when the hip is in 30° flexion, the hamstrings (semimembranosus) show a different force vector angle in comparison with 90° activation. Activities holding the hip in 30° hip flexion can reproduce SN complaints when the hamstrings are activated. Conversely, patients with IFI are more comfortable sitting, and walking during terminal hip extension when the space between ischium and the lesser trochanter is diminished, exacerbating the pain.[10,23] This diminished space is the location of the SN. If the normal biomechanics of this space is disrupted, the SN has the dynamic potential to be impinged.

The influence of limited hip range of motion on spine mobility and function has been shown as one of the causes of chronic low back pain.[30–34] Patients with IFI may present associated symptoms of low back pain due to the limited hip extension. This clinical observation was confirmed by Gómez-Hoyos[35] in a cadaveric study. Limiting hip extension by decreasing the ischiofemoral space resulted in increased intrafacet joint pressure of the lumbar spine (L3–L4 and L4–L5). A complete physical

Downloaded from ClinicalKey.com at Ohio State University Libraries August 26, 2016.
For personal use only. No other uses without permission. Copyright ©2016. Elsevier Inc. All rights reserved.

examination of the hip must comprise a lumbar spine evaluation; in the same way, cases of low back pain should also include a hip evaluation.

The physical examination to diagnose DGS, hamstrings syndrome, and IFI should be included in the standard hip joint evaluation protocol when posterior hip pain is a complaint (**Table 1**).[10,11] In the present work, a brief description of the key points and the main 6 tests previously validated to diagnose posterior hip pain are given. All hip joint evaluations should assess the 3 planar kinematic axes, comprising a gait analysis followed by an evaluation in the seated, supine, lateral, and prone positions.

The observation of the biomechanical axis alignment will provide information of the pelvic positioning. In normal osseous morphologic conditions, the balance between hip flexors and extensors influences the pelvic positioning in the sagittal axis. An abnormal pelvic positioning, posteriorly or anteriorly, has been associated with weakness and/or stiffness of the hip muscles involved with pelvic positioning, and this factor may contribute to the development of DGS and IFI.[36–39]

During the analysis of gait, the morphologic abnormalities of the hip joint, muscle weakness, pain patterns, and the long stride–walking test can provide important

Table 1
Steps for diagnosis and treatment of posterior hip pain

Condition	Diagnosis	Treatment
Ischiofemoral impingement	Assess structural contributing factors Distal pain lateral to the ischium Gait – Long stride walking (recreation of pain) vs short stride (alleviated pain) Ischiofemoral impingement test	• Nonoperative: ○ Abductor strengthening ○ Arch support ○ Injections ○ Limit stride length in sports and activities of daily living • Operative: ○ Open resection of the LT ○ Distalization of the LT ○ Ischioplasty: associated semimembranosus tear ○ Ischioplasty + LT resection: recreate normal ○ THA: associated osteoarthritis ○ Femoral osteotomy ○ Endoscopic LT resection
Hamstring syndrome	Pain lateral to the ischium Gait: heel strike (recreation of pain) Active hamstring test: 30° vs 90°	• Hamstring + IFI → ischioplasty + repair • Hamstring + sciatic nerve entrapment → open with neuromonitoring
Deep gluteal syndrome	Consider spine, SI, intrapelvis and gluteal space pathologies Pain proximal at the level of the piriformis Passive piriformis stretch test Active piriformis test	• Nonoperative: ○ Physical therapy: pelvic floor therapy ○ Guided injections ○ Steroids and neuromodulators • Operative: ○ Open sciatic nerve decompression ○ Intrapelvic laparoscopic decompression ○ Endoscopic decompression

Abbreviations: IFI, ischiofemoral impingement; LT, lesser trochanter; SI, sacroiliac joint; THA, total hip arthroplasty.

Downloaded from ClinicalKey.com at Ohio State University Libraries August 26, 2016.
For personal use only. No other uses without permission. Copyright ©2016. Elsevier Inc. All rights reserved.

information to differentiate hamstrings syndrome and IFI. As previously cited, IFI was found to be more frequent in subjects with increased femoral version.[22,23] An internal foot progression angle during gait can present an increased femoral version and consequently is found with IFI.[22] A positive Trendelenburg sign can happen due to weakness of the gluteus medius muscle. A combination of hip adduction and pelvic tilt associated with rotational motion in axial load may contribute to lesser trochanteric impingement against the ischium, producing IFI symptoms.[10,22,23] The patterns of pain manifestation during gait can provide a key point for the diagnosis of posterior hip pain pathologies. During the initial heel strike, the hamstrings muscles act eccentrically, decelerating the leg during heel strike. Subjects referring pain lateral to the ischium during this specific motion may present a positive sign for proximal chronic or acute hamstrings tears. Differentially, the long stride–walking test is 1 of 2 tests used to diagnose IFI, and is a critical diagnosis tool.[3,4] Gómez-Hoyos and colleagues[3] showed this test with a sensitivity of 0.94 and specificity of 0.85 in the diagnosis of IFI. The long stride–walking test is positive when the patient refers pain lateral to the ischium during *terminal extension* that is relieved with short steps[4] (**Fig. 3**).

The palpation of the gluteal structures in the seated position using the ischial tuberosity as a reference point can also guide and distinguish sources of posterior hip pain[10] (**Fig. 4**). With the patient in sitting position, the active hamstrings test is performed. The patient is asked to actively flex the knee (positioned at 30° and 90° of

Fig. 3. (*A*) Short stride walking: no pain. (*B*) Long stride walking: recreation of pain lateral to the ischium.

Downloaded from ClinicalKey.com at Ohio State University Libraries August 26, 2016.
For personal use only. No other uses without permission. Copyright ©2016. Elsevier Inc. All rights reserved.

Fig. 4. Hand positioning for palpation of the deep gluteal space. From medial to lateral, the pudendal nerve entrapment is considered in cases of pain sensation medial to the ischium (1) in association with a tender sacrotuberous ligament, pain lateral to the ischium may represent hamstrings syndrome (2) or IFI (3), and finally, pain sensation at the sciatic notch characterizes the piriformis muscle (4).

flexion) against the resistance of the examiner. Reproduction of pain and/or complaint may represent a proximal hamstring tendon injury, hamstrings syndrome, and SN subluxation into the ischial tunnel.[10] Proximal from distal SN entrapment can be distinguished by the location of the symptomatic pain recreation.

From proximal to distal, the diagnosis of posterior hip pain can be differentiated through 2 tests in a seated position. The piriformis stretch test is performed (sensitivity of 0.52, specificity of 0.90) to diagnose DGS as the source of posterior hip pain. The test is performed with a flexion, adduction with internal rotation. The examiner extends the knee (engaging the SN) and passively moves the flexed hip into adduction with internal rotation while palpating the piriformis muscle lateral to the ischium or proximally at the sciatic notch. A positive test is the re-creation of the posterior pain at the level of the piriformis muscle lateral to the ischium or external rotators[5] (**Fig. 5**).

Finally, moving the patient to lateral decubitus, the last 2 tests to differentiate IFI and DGS are assessed. The active piriformis test showed sensitivity of 0.78 and specificity of 0.80 to diagnose DGS, and when used in association with the passive piriformis stretch test are major contributors to diagnose SN entrapment by the piriformis muscle. The patient is instructed to drive the heel into the examination table, initiating active hip abduction and external rotation against resistance from the examiner. Similar to the piriformis stretch test, a positive test is the presence of posterior pain at the level of the piriformis or external rotators.[5] While the patient is in lateral decubitus, the IFI test is performed. The pain is produced when the examiner extends the hip in association to adduction or in neutral position. To confirm the suspicion of IFI, the examiner extends the hip in neutral abduction with no symptom of pain, proving the presence of an impinging pathology. The IFI test showed a sensitivity of 0.82 and specificity of 0.85, and in combination with the long strides walking are used to identify IFI[3] (**Fig. 6**).

DIFFERENTIAL DIAGNOSIS

During the comprehensive history and physical examination, the examiner must be aware of DGS symptoms simulated by intrapelvic and extrapelvic structures. Cyclic

Downloaded from ClinicalKey.com at Ohio State University Libraries August 26, 2016.
For personal use only. No other uses without permission. Copyright ©2016. Elsevier Inc. All rights reserved.

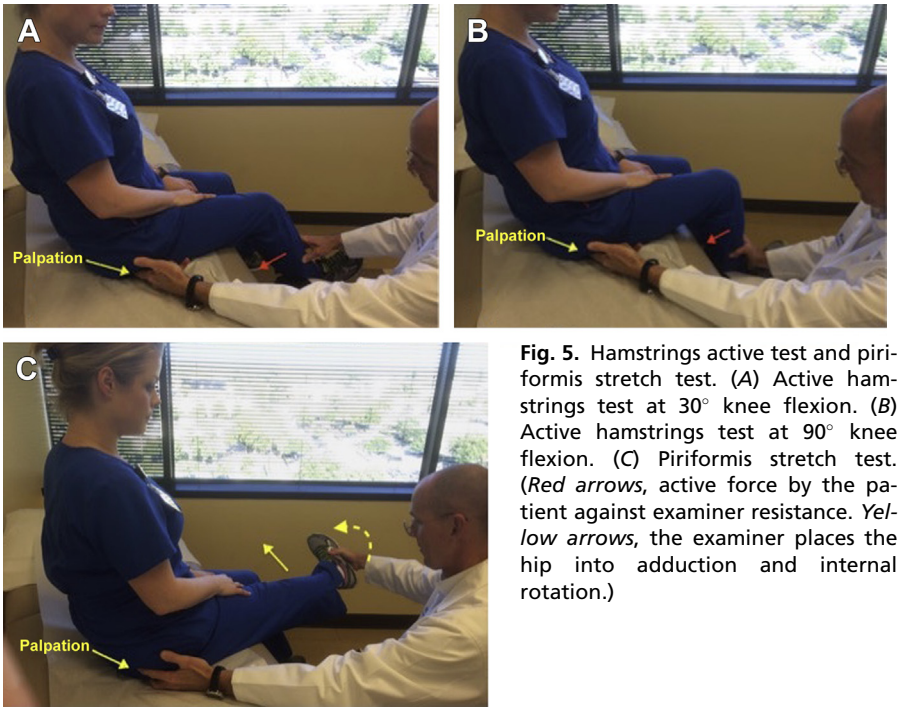

Fig. 5. Hamstrings active test and piriformis stretch test. (*A*) Active hamstrings test at 30° knee flexion. (*B*) Active hamstrings test at 90° knee flexion. (*C*) Piriformis stretch test. (*Red arrows*, active force by the patient against examiner resistance. *Yellow arrows*, the examiner places the hip into adduction and internal rotation.)

pain with a history of urogynecologic conditions (endometriosis, bladder or bowel issues, and dysmenorrhea) may indicate an intrapelvic SN entrapment.[10,16,17] Pudendal nerve entrapment is an isolated condition that may be associated with DGS that can be differentiated by a pain location and typical characteristics. Patients with pudendal nerve entrapment present with pain medial to the ischium and sensations of burning, tearing, stabbing lightninglike, electrical, sharp shooting, and/or foreign body sensation that is made worse with sitting (alleviated with toilet stool sitting) and reduced with standing.[17,40] The nerve can be entrapped in more than one location (piriformis, obturator internus muscles, sacrotuberous and sacrospinous ligaments, or the falsiform process), and a pelvic floor manual test performed by a trained physical therapist will assist the diagnosis and relationship of these intrapelvic conditions.[17,40,41]

IMAGING AND ANCILLARY TESTS

The standard imaging studies include the standing anterior-posterior pelvis, false profile, and lateral images. All intra-articular pathology is ruled out through a comprehensive history and physical examination assessing the 5 levels of osseous, capsulolabral, musculotendinous, neurovascular structures, and the kinematic chain. Specifically in posterior hip cases, the T3 MRI is performed to rule out intrapelvic sources of SN entrapment versus extrapelvic SN entrapment. The extrapelvic MRI patient positioning is important for IFI assessment. The feet are secured in a neutral walking position, which will most closely simulate a dynamic assessment of the ischiofemoral space. If the feet are not secured in this functional position, a false impression of

Downloaded from ClinicalKey.com at Ohio State University Libraries August 26, 2016.
For personal use only. No other uses without permission. Copyright ©2016. Elsevier Inc. All rights reserved.

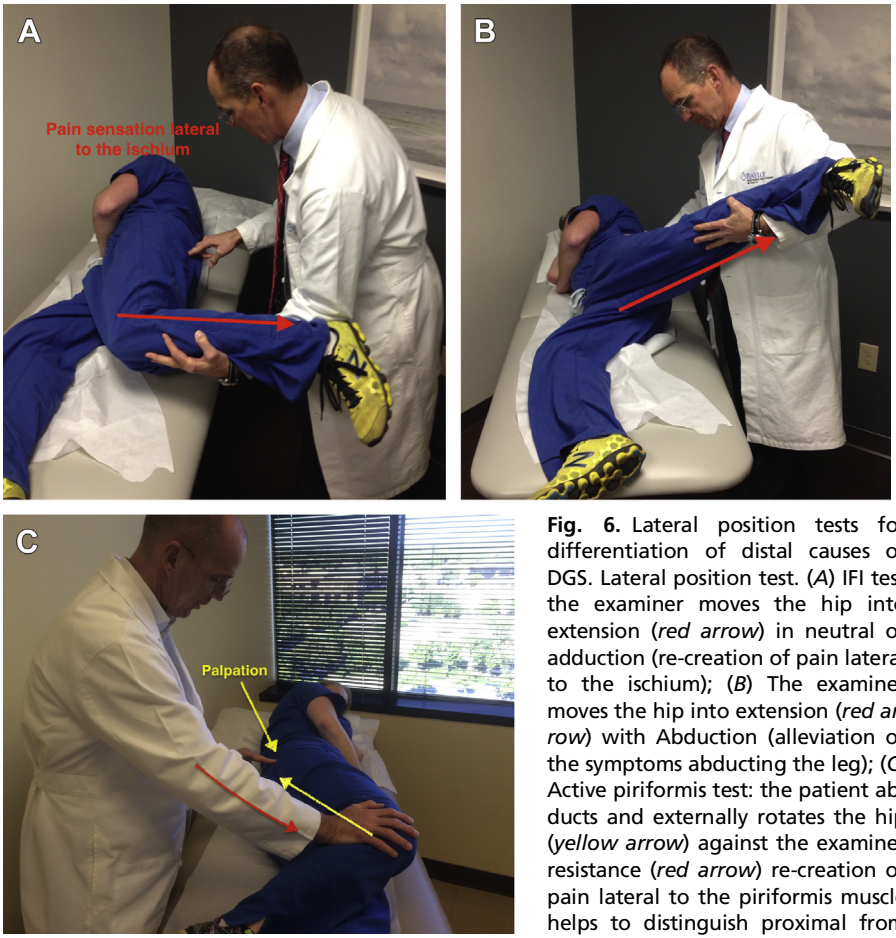

Fig. 6. Lateral position tests for differentiation of distal causes of DGS. Lateral position test. (*A*) IFI test the examiner moves the hip into extension (*red arrow*) in neutral or adduction (re-creation of pain lateral to the ischium); (*B*) The examiner moves the hip into extension (*red arrow*) with Abduction (alleviation of the symptoms abducting the leg); (*C*) Active piriformis test: the patient abducts and externally rotates the hip (*yellow arrow*) against the examiner resistance (*red arrow*) re-creation of pain lateral to the piriformis muscle helps to distinguish proximal from distal involvement etiologies.

decreased ischiofemoral space could occur. The assessment of the semimembranosus and its orientation to the lateral ischium is best visualized on T2 axial or T2 coronal imaging. This view allows for the detection of a partial tear or undersurface tears of the semimembranosus. In cases of active subluxation of the semimembranosus, dynamic MRI testing and dynamic ultrasound are useful. In dynamic ultrasound, the patient is placed in the prone position and the patient performs a bicycling motion with active hamstring contraction. The activated semimembranosus will sublux into the ischial tunnel recreating the radicular pain of the SN. Scarring in this region can be assessed by T1 and T2 MRI in the axial and coronal planes. The T3 MRI of the intrapelvis is used for gynecologic and vascular entrapments of the SN and/or its roots. This type of partial tear with subluxation into the ischial tunnel can be correlated with the physical examination assessment with the knee extended and the hip abducted.

Ancillary testing can include electromyography (EMG); however, it has not been found to be useful. If EMG is used, the testing should be performed in a dynamic modality with the knee in extension and the hip in flexion and abduction and the symptomatic side is compared with the nonsymptomatic side looking at neural latency.

Downloaded from ClinicalKey.com at Ohio State University Libraries August 26, 2016.
For personal use only. No other uses without permission. Copyright ©2016. Elsevier Inc. All rights reserved.

Injection tests have been advocated for supporting the diagnosis of posterior extra-articular and intra-articular hip disorders. Anesthetic injection to the piriformis muscle can provide relief. Guided injections using computed tomography (CT), fluoroscopy, ultrasound, or MRI increase accuracy to the correct injection site. Ultrasound, as described previously, in addition to injection testing, is beneficial in the exact diagnosis of either IFI or hamstring tears involvement. Injection tests can include dynamic fluoroscopy to assess the IFS, or visualizing the dynamic recreation of the IF pain with the hip in terminal hip extension. Fluoroscopy can also be helpful in recreating greater trochanteric SN impingement, which can exist proximally. The ligamentous constraints of the hip do affect the overall kinematics of the hip and can affect the exact locations of impingement. This is evidenced through a multilayer effect, not just osseous but also capsulolabral, which can influence any of the other structures above or below the primary area of complaint.

TREATMENT

Nonoperative Treatment

The nonoperative treatment of posterior hip pain is a result of a comprehensive history and physical examination. A combination of physical therapy, nonsteroidal intramuscular injections, neuropsychological evaluation/treatment, and home exercises program are used as a standard protocol for nonoperative treatment.[10,41]

The physical therapy treatment for individuals with hamstrings syndrome, IFI, or DGS must involve associated factors such as lumbosacral spine alignment and stabilization, pelvic floor, and intra-articular structures. The intervention strategy for those with posterior hip pain is directed to rebalance the muscle-articular functioning of the hip/pelvis and spine through soft tissue mobilization, stretching and strengthening exercises, and aerobic conditioning. In cases of pelvic floor and urogynecological involvement, a pelvic floor therapy is applied to the treatment plan.

Nonsteroidal CT-guided injections are used as a diagnosis tool and treatment alternative. For those with DGS, IFI, and hamstrings syndrome, the utilization of injections can help to differentiate the source of pain, when correctly administered at the structure under investigation, producing relief of pain.[10,42,43] The posterior hip pain may have a chronic pathologic characteristic, affecting quality of life and mental health. A neuropsychiatric evaluation is required and a treatment is administered when appropriated.[41]

In addition to the clinical treatment, educational strategies addressing activities of daily living and a handout containing a home exercise program is delivered. The exercises are directed to increase the SN mobility into the deep gluteal space, combining the piriformis stretch, neural mobilization and SN–greater trochanter mobilization (hip circumduction) (**Fig. 7**).[41]

Surgical Treatment

In the event that a patient does not achieve pain relief with conservative treatment, surgical intervention is considered. The surgical treatment chosen will depend on both the clinical diagnosis and imaging evaluation, and to the patients' response to targeted injections during the conservative treatment stage.

The surgical treatment of DGS involving IFI or hamstrings avulsion must address the relevant pathology. The goal of surgery is to restore normal anatomy and normal neural function. The correct surgical procedure to address IFI encompasses the assessment of the entire biomechanical axis, as previously described. These procedures vary and include both open and endoscopic techniques to treat the conditions. Cases of IFI

Downloaded from ClinicalKey.com at Ohio State University Libraries August 26, 2016.
For personal use only. No other uses without permission. Copyright ©2016. Elsevier Inc. All rights reserved.

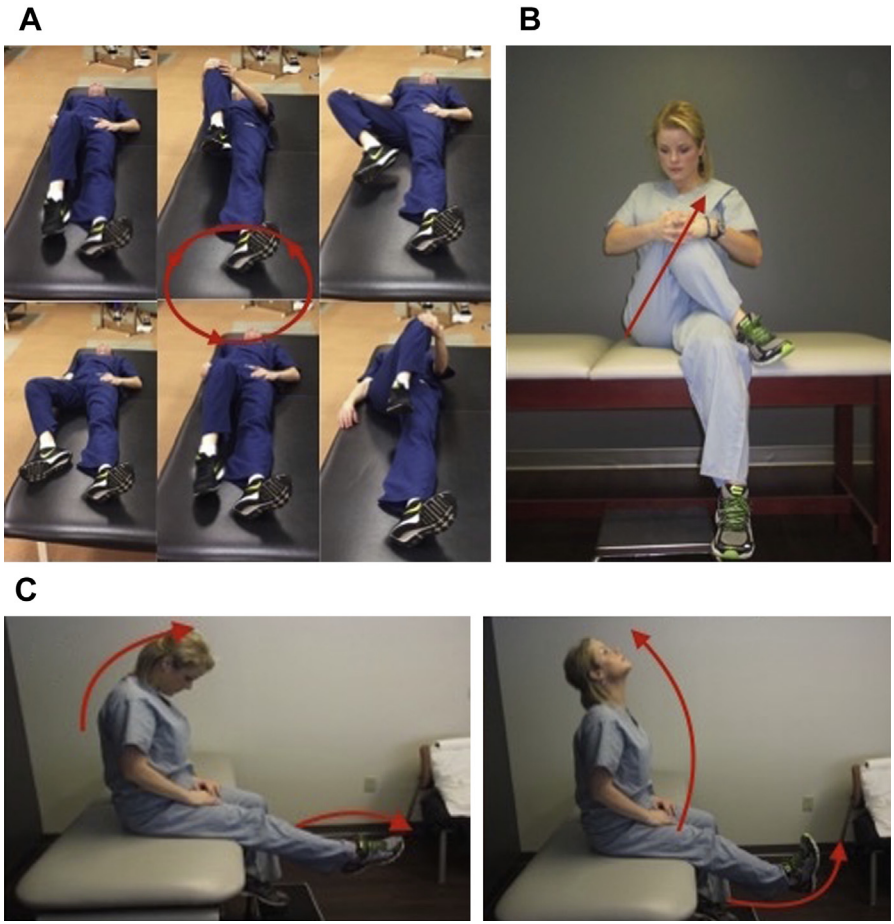

Fig. 7. Home exercise program. (*A*) Hip circumduction; (*B*) piriformis stretch; (*C*) neural mobilization. (*Red arrows,* direction of active motion by the patient.)

may be easily resolved with simple solutions, such as a shoe lift to moderate leg length inequality, or addressing a hyper-pronated hind foot by bringing the extremity into less internal rotation during midfoot stance phase. The presence of genu valgum or coxa valga may influence the IFS and result in painful pathologies. If the femoral torsion is greater than 30° of femoral anteversion, one must consider the need for a femoral de-rotational osteotomy, depending on the 3 planar osseous planar assessments. Each case should have a McKibbin index, acetabular and femoral version performed. The entire biomechanical axis in addition to the bimalleolar axis in determining the proper course of treatment is assessed. In cases of simple IFI that have failed conservative treatment, surgical intervention may be required.

The endoscopic technique was proven successful as reported by Hatem and colleagues[4] with the modified Harris Hip Score (mHHS), visual analog scale, and return to sport significantly improving after 2 years of follow-up. Surgical treatment for ischiofemoral impingement requires complete 3-planar valuation of the osseous anatomy involved with IFI. The endoscopic treatment options can involve open or endoscopic techniques to restore the normal anatomy. The goal is a functionally normal

Downloaded from ClinicalKey.com at Ohio State University Libraries August 26, 2016.
For personal use only. No other uses without permission. Copyright ©2016. Elsevier Inc. All rights reserved.

ischiofemoral space, the distance between the ischium and lesser trochanter. This may involve isolated lesser trochanterplasty and ischioplasty. The procedure is performed similar to Hatem and colleagues.[4] The patient is placed supine on a traction table with 20° contralateral tilt. Three portals are used: anterolateral, posterolateral, and auxiliary distal at level of lesser trochanter, as seen in **Fig. 8**. Traction is used for a maximum of 15 minutes while the intra-articular space was arthroscopically examined, with the remainder of the procedure performed without traction. A 70° high-definition arthroscope is used in the anterolateral portal, while the posterolateral and auxiliary distal portal are primarily used for a probe, arthroscopic burr, curved retractors, or arthroscope. Resection of the quadratus femoris is necessary to provide a window to access the lesser trochanter between the medial circumflex femoral artery and first perforating femoral artery. Lesser trochanteroplasty of the posterior one-third is then performed to obtain a functionally normal ischiofemoral space. Dynamic hip movements of adduction-extension and internal-external rotation are used to verify the lesser trochanter decompression.[4]

The cases presenting with hamstrings avulsions in conjunction with IFI can be addressed with a combination of ischioplasty and hamstrings repair, or with lesser trochanteroplasty. The goal is to recreate the standard IFS so as to achieve normal terminal hip extension, and to avoid any kinematic lumbar consequences. Identifying and decompressing the SN, which is often concomitantly involved, is critical to achieving optimal results. Chronic hamstring avulsions resulting in posterior hip pain can be repaired using an open or endoscopic approach. Full endoscopic approaches

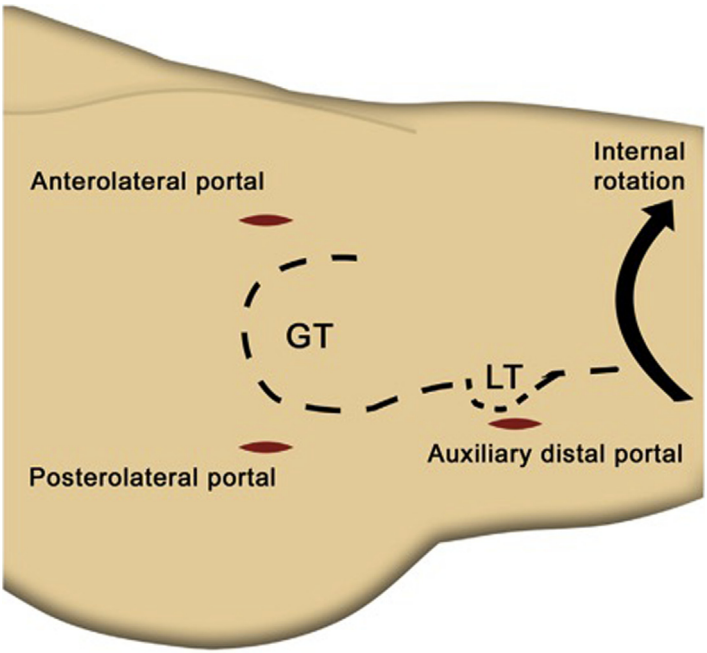

Fig. 8. Arthroscopic portal placement for IFI. Three portals are used: anterolateral, posterolateral, and auxiliary distal at the level of the lesser trochanter (LT). GT, greater trochanter. (*Reprinted from* Hatem MA, Palmer IJ, Martin HD. Diagnosis and 2-year outcomes of endoscopic treatment for ischiofemoral impingement. Arthroscopy 2015;31(2):241; with permission.)

Downloaded from ClinicalKey.com at Ohio State University Libraries August 26, 2016.
For personal use only. No other uses without permission. Copyright ©2016. Elsevier Inc. All rights reserved.

to hamstring repair have increased in popularity due to complications associated with open techniques, including extensive tissue exposure, and proximity of incision to perianal zone[2,44]; however, the procedure becomes very difficult with retractions greater than 5 cm.[44]

The open approach for hamstrings avulsion is considered in late repairs, as there is a larger amount of scar tissue formation.[45] The patient is placed in the prone position with the knees in a flexed position. Depending on the amount of distal retraction, an incision may be either longitudinal or transverse to the gluteal fold. The fascia overlaying the hamstring compartment is exposed through blunt dissection of the subcutaneous tissue, and retraction of the gluteus maximus. Identification of the SN is necessary to prevent iatrogenic injury. The injured hamstrings tendons and anatomic insertion point of the common hamstrings tendon on the ischial tuberosity are identified. Following fibrous tissue debridement and suture anchor placement, the hamstrings are repaired. In the case of chronic tears, or tears older than 3 months, Achilles allograft tissue may be required.[45] The open surgical technique to treat hamstrings avulsions, both acute and chronic, is well documented, and it is recommended that a complete review of literature be performed to identify an appropriate procedure.[45–50]

An alternative approach is a mini-open surgical technique, which is assisted by dry endoscopy and neuromonitoring. The neuromonitoring reduces risk of intraoperative nerve damage.[51–53] The mini-open transgluteal approach is performed with the patient in a prone position. The ischial tuberosity and ischiofemoral space are identified under fluoroscopy, and an 8-cm transverse line is drawn. Hamstrings are accessed through the gluteus maximus two-thirds proximal and one-third distal to the muscle. The size and severity of hamstrings avulsion can then be monitored with the arthroscope through the incision. Once the degenerated tendon fibers and bursa are removed, the footprint of the torn tendon is decorticated with a 4.0-mm burr. Hamstrings reattachment to the normal anatomic footprint is performed with 4.5-mm sutures under direct fluoroscopic visualization.

The open technique may demonstrate a partially, but symptomatically, healed semimembranosus in partial healed and symptomatic avulsion. These avulsions are closed through the initial opening, which is easily identified in the partial tear once the small fibers are opened on the posterolateral corner of the ischium. The ischial angle also takes into consideration the degree of ischioplasty resection, with the overall goal of creating a flat surface by which the semimembranosus can be repaired with the recreation of the proper IFS. Should the ischium be resected, and the IFS is still diminished, it is recommended to internally rotate and approach the lesser trochanter through the central portion of the quadratus femoris.

Nerve mobility is assessed before closure and further adhesions, both proximally and distally, should be assessed. The wound is meticulously closed through the maximus fascia in addition to the subcutaneous tissue and a running subcuticular plastics closure. A sterile dressing is applied and left in place for the first 5 days. The knee is placed into flexion and remains in flexion throughout the closure. The knee is left in a locked position at 45° flexion for 3 to 4 weeks, or with more extension as tolerated by the SN. Physical therapy is initiated with the SN mobilization exercises as described in the following section.

Postoperative Treatment

The postoperative rehabilitation of IFI, DGS, and hamstrings syndrome surgeries represents a very important piece of treatment of posterior hip pain. The treatment

Downloaded from ClinicalKey.com at Ohio State University Libraries August 26, 2016.
For personal use only. No other uses without permission. Copyright ©2016. Elsevier Inc. All rights reserved.

Table 2
Postoperative rehabilitation summary

Condition	Associated Findings	Specific Care	Time
IFI	• Limited hip extension; • Poor lumbopelvic stabilization; • Low back pain; • G. med + max. weakness; • Adductors contracture; • Increased femoral version.	• Neutral hip flexors stretching (0°) first 4 wk; • Crutches and partial weight bearing: 4 wk; • Lumbopelvic alignment and stabilization to control hip extension; • Immediate G. med + max. strengthening; • Reestablish the plantar arc (if necessary in cases of hyperpronation); • Avoid pelvic drop or lower extremity in excessive adduction and internal rotation during weight bearing.	12 (wk)
Hamstring syndrome	• Hamstring weakness associated with tendon retractions (in case of complete rupture); • Decreased SN mobility; • G. max weakness; • Altered pelvic sagittal alignment (anteriorly or posteriorly)	• Neutral hip flexors stretching (0°): 4 wk; • Lumbopelvic alignment and stabilization; • Crutches (6–8 wk) + flat foot during gait; • Knee brace locked between 30° and 45° flexion (45° during exercises): gradual extension with patient tolerance; • Sciatic nerve mobilization exercises in cases of scars between HS and SN; • First 3 wk: short stride walking; • Full ROM: 6 wk = hamstring strengthening.	24 wk–1 y
DGS	• Low back pain; • Piriformis and/or obturator internus contracture; • Pelvic floor issues; • External rotators weakness; • Femur in excessive adduction and internal rotation during functional activities;	• Neutral hip flexors stretching (0°): 4 wk; • Lumbopelvic alignment and stabilization; • Avoid neurapraxia: constant neural mobilization; • Crutches (6–8 wk) + flat foot during gait; • Knee brace locked between 30°and 45° flexion (45° during exercises): gradual extension with patient tolerance; • Passive distal (cervical and ankle) nerve glides: week 2, increase tension with patient pain tolerance; • After week 3, increase 10° knee extension per week (patient pain tolerance); • Total hip/knee ROM: week 8.	24 wk–2 y

Abbreviations: DGS, deep gluteal syndrome; G max, gluteus maximus; G med, gluteus maximus; HS, hamstring; IFI, ischiofemoral impingement; ROM, range of motion; SN, sciatic nerve.

Downloaded from ClinicalKey.com at Ohio State University Libraries August 26, 2016.
For personal use only. No other uses without permission. Copyright ©2016. Elsevier Inc. All rights reserved.

strategy follows the same concept based on the preoperative findings and approaches.

The therapist should be comfortable with the anatomy and biomechanics of the repaired tissues, as previously was demonstrated the intimate relationship between those structures in the deep gluteal space. Strategies directed to improve the lumbopelvic stabilization, maintaining and increasing the SN mobility into the deep gluteal space are the overall goals for those conditions. **Table 2** summarizes the key points to follow in the postoperative rehabilitation.

SUMMARY

In conclusion, IFI and hamstrings avulsions involving the SN are recognized through a comprehensive history and physical examination using ancillary testing and 3 planar radiographic assessments. Outcomes are dependent on patient compliance and the understanding of the entire anatomy, biomechanics, clinical presentation, and open versus endoscopic treatment options.

REFERENCES

1. Martin HD, Shears SA, Johnson JC, et al. The endoscopic treatment of sciatic nerve entrapment/deep gluteal syndrome. Arthroscopy 2011;27(2):172–81.
2. Gómez-Hoyos J, Reddy M, Martin HD. Dry endoscopic-assisted mini-open approach with neuromonitoring for chronic hamstring avulsions and ischial tunnel syndrome. Arthrosc Tech 2015;4(3):e193–9.
3. Gomez-Hoyos J. Martin R. Schroder R. et al. Accuracy of two clinical tests for ischiofemoral impingement in patients with posterior hip pain and endoscopically confirmed diagnosis. Arthroscopy, in press.
4. Hatem MA, Palmer IJ, Martin HD. Diagnosis and 2-year outcomes of endoscopic treatment for ischiofemoral impingement. Arthroscopy 2015;31(2):239–46.
5. Martin HD, Kivlan BR, Palmer IJ, et al. Diagnostic accuracy of clinical tests for sciatic nerve entrapment in the gluteal region. Knee Surg Sports Traumatol Arthrosc 2014;22(4):882–8.
6. Patti JW, Ouellette H, Bredella MA, et al. Impingement of lesser trochanter on ischium as a potential cause for hip pain. Skeletal Radiol 2008;37(10):939–41.
7. Torriani M, Souto SCL, Thomas BJ, et al. Ischiofemoral impingement syndrome: an entity with hip pain and abnormalities of the quadratus femoris muscle. AJR Am J Roentgenol 2009;193(1):186–90.
8. Orava S. Hamstring syndrome. Oper Tech Sports Med 1997;5(3):143–9.
9. Young IJ, van Riet RP, Bell SN. Surgical release for proximal hamstring syndrome. Am J Sports Med 2008;36(12):2372–8.
10. Martin HD, Reddy M, Gomez-Hoyos J. Deep gluteal syndrome. J Hip Preserv Surg 2015;2(2):99–107.
11. Martin HD, Palmer IJ. History and physical examination of the hip: the basics. Curr Rev Musculoskelet Med 2013;6:219–25.
12. Johnson K, Rochester M. Impingement of the lesser after on the ischial ramus total. J Bone Joint Surg Am 1977;59(2):268–9.
13. Miller BSL, Gill J, Webb GR. The proximal origin of the hamstrings and surrounding anatomy encountered during repair. J Bone Joint Surg Am 2007;89-A(805):44–8.
14. Dierckman BD, Guanche CA. Endoscopic proximal hamstring repair and ischial bursectomy. Arthrosc Tech 2012;1(2):e201–7.

Downloaded from ClinicalKey.com at Ohio State University Libraries August 26, 2016.
For personal use only. No other uses without permission. Copyright ©2016. Elsevier Inc. All rights reserved.

15. Miller SL, Webb GR. The proximal origin of the hamstrings and surrounding anatomy encountered during repair. Surgical technique. J Bone Joint Surg Am 2008; 90(Suppl 2):108–16.
16. Hibner M, Desai N, Robertson LJ, et al. Pudendal neuralgia. J Minim Invasive Gynecol 2010;17(2):148–53.
17. Filler AG. Diagnosis and treatment of pudendal nerve entrapment syndrome subtypes: imaging, injections, and minimal access surgery. Neurosurg Focus 2009; 26(2):E9.
18. Beltran L, Ghazikhanian V, Padron M, et al. The proximal hamstring muscle-tendon-bone unit: a review of the normal anatomy, biomechanics, and pathophysiology. Eur J Radiol 2012;81(12):3772–9.
19. Bierry G, Simeone FJ, Borg-Stein JP, et al. Sacrotuberous ligament: relationship to normal, torn, and retracted hamstring tendons on MR images. Radiology 2014;271(1):162–71.
20. Mercer SR, Woodlai SJ, Kennedi E. Anatomy in practice?: the sacrotuberous ligament. NZ J Physiother 2005;33(3):91–4.
21. Gomez-Hoyos J, Schroder R, Reddy M, et al. Is there a relationship between psoas impingement and increased trochanteric retroversion? J Hip Preserv Surg 2015;2(2):164–9.
22. Gómez-Hoyos J, Schroder R, Reddy M, et al. Femoral neck anteversion and lesser trochanter retroversion in patients with ischiofemoral impingement: a case-control magnetic resonance imaging study. Arthroscopy 2015. http://dx.doi.org/10.1016/j.neuron.2014.02.016.
23. Schroder R, Reddy M, Hatem M, et al. A MRI study of the lesser trochanteric version and its relationship to proximal femoral osseus anatomy. J Hip Preserv Surg 2015;1–7. http://dx.doi.org/10.1093/jhps/hnv067.
24. Coppieters MW, Alshami AM, Babri AS, et al. Strain and excursion of the sciatic, tibial, and plantar nerves during a modified straight leg raising test. J Orthop Res 2006;24:1883–9.
25. Coppieters MW, Andersen LS, Johansen R, et al. Excursion of the sciatic nerve during nerve mobilization exercises: an in vivo cross-sectional study using dynamic ultrasound imaging. J Orthop Sports Phys Ther 2015;45(10):731–7.
26. Wall EJ, Massie JB, Kwan MK, et al. Changes in nerve conduction under tension. J Bone Joint Surg Br 1992;74-B(1):126–9.
27. Boyd BS, Puttlitz C, Gan J, et al. Strain and excursion in the rat sciatic nerve during a modified straight leg raise are altered after traumatic nerve injury. J Orthop Res 2005;23(4):764–70.
28. Khoury A. Schroder R. Gomez-Hoyos J. et al. The effects of hip abduction on sciatic nerve biomechanics during terminal hip flexion. ISHA - Int Meet. Cambridge (United Kingdom): September 24–26, 2015.
29. Mohtadi NGH, Griffin DR, Pedersen ME, et al. The development and validation of a self-administered quality-of-life outcome measure for young, active patients with symptomatic hip disease: the international hip outcome tool (iHOT-33). Arthroscopy 2012;28(5):595–610.e1.
30. Ellison JB, Rose SJ, Sahrmann S. Patterns of hip rotation range of motion: a comparison between healthy subjects and patients with low back pain. Phys Ther 1990;70(9):537–41.
31. Cibulka MT, Sinacore DR, Cromer GS, et al. Unilateral hip rotation range of motion asymmetry in patients with sacroiliac joint regional pain. Spine J 1998;23(9): 971–1082.

Downloaded from ClinicalKey.com at Ohio State University Libraries August 26, 2016.
For personal use only. No other uses without permission. Copyright ©2016. Elsevier Inc. All rights reserved.

32. Vad VB. Low back pain in professional golfers: the role of associated hip and low back range-of-motion deficits. Am J Sports Med 2004;32(2):494–7.
33. Van Dillen LR, Gombatto SP, Collins DR, et al. Symmetry of timing of hip and lumbopelvic rotation motion in 2 different subgroups of people with low back pain. Arch Phys Med Rehabil 2007;88(3):351–60.
34. Van Dillen LR, Bloom NJ, Gombatto SP, et al. Hip rotation range of motion in people with and without low back pain who participate in rotation-related sports. Phys Ther Sport 2008;9(2):72–81.
35. Gómez-Hoyos J, Khoury A, Schroder R, et al. The hip-spine effect: A cadaveric study of ischiofemoral impingement in hip extension effecting loads in lumbar facet joints. Arthroscopy, in press.
36. Halbertsma JP, Göeken LN, Hof AL, et al. Extensibility and stiffness of the hamstrings in patients with nonspecific low back pain. Arch Phys Med Rehabil 2001;82(2):232–8.
37. Neumann DA. Kinesiology of the hip: a focus on muscular actions. J Orthop Sports Phys Ther 2010;40(2):82–94.
38. Ekstrom RA, Donatelli RA, Carp KC. Electromyographic analysis of core trunk, hip, and thigh muscles during 9 rehabilitation exercises. J Orthop Sports Phys Ther 2007;37(12):754–62.
39. Sullivan MK, Dejulia JJ, Worrell TW. Effect of pelvic position and stretching method on hamstring muscle flexibility. Med Sci Sports Exerc 1992;24(12):1383–9.
40. FitzGerald MP, Kotarinos R. Rehabilitation of the short pelvic floor. II: Treatment of the patient with the short pelvic floor. Int Urogynecol J Pelvic Floor Dysfunct 2003; 14(4):269–75 [discussion: 275].
41. Schroder R. Gomez-Hoyos J. Martin R. et al. Non-operative treatment of deep gluteal pain: a case series of seven patients. ISHA - Int Meet. Cambridge (United Kingdom): September 24–26, 2015.
42. Michel F, Decavel P, Toussirot E, et al. Piriformis muscle syndrome: diagnostic criteria and treatment of a monocentric series of 250 patients. Ann Phys Rehabil Med 2013;56(5):371–83.
43. Fishman LM, Dombi GW, Michaelsen C, et al. Piriformis syndrome: diagnosis, treatment, and outcome–a 10-year study. Arch Phys Med Rehabil 2002;83(3): 295–301.
44. Guanche CA. Hamstring injuries. J Hip Preserv Surg 2015;2(2):116–22.
45. Fetzer GB, Fischer DA. Hamstrings injuries. In: Guanche C, editor. Hip and pelvis injuries in sports medicine. 1st edition. Philadelphia: Lippincott Williams & Wilkins; 2010. p. 181–92.
46. Mica L, Schwaller A, Stoupis C, et al. Avulsion of the hamstring muscle group: a follow-up of 6 adult non-athletes with early operative treatment: a brief report. World J Surg 2009;33(8):1605–10.
47. Sallay P, Ballard G, Hamersly S, et al. The effect of collar on aseptic loosening and proximal femoral bone resorption in hybrid total hip arthroplasty. Orthopedics 2008;31(3):227.
48. Lempainen L, Sarimo J, Mattila K, et al. Proximal hamstring tendinopathy: results of surgical management and histopathologic findings. Am J Sports Med 2009; 37(4):727–34.
49. Chakravarthy J, Ramisetty N, Pimpalnerkar A, et al. Surgical repair of complete proximal hamstring tendon ruptures in water skiers and bull riders: a report of four cases and review of the literature. Br J Sports Med 2005;39(8):569–72.
50. Cross M, Vandersluis R, Wood D, et al. Surgical repair of chronic complete hamstring rupture in the adult patient. Am J Sports Med 1998;26(6):785–8.

Downloaded from ClinicalKey.com at Ohio State University Libraries August 26, 2016.
For personal use only. No other uses without permission. Copyright ©2016. Elsevier Inc. All rights reserved.

51. Porat M, Orozco F, Goyal N, et al. Neurophysiologic monitoring can predict iatrogenic injury during acetabular and pelvic fracture fixation. HSS J 2013;9(3):218–22.
52. Calder HB, Mast J, Johnstone C. Intraoperative evoked potential monitoring in acetabular surgery. Clin Orthop Relat Res 1994;305:160–7.
53. Baumgaertner MR, Wegner D, Booke J. SSEP monitoring during pelvic and acetabular fracture surgery. J Orthop Trauma 1994;8:127–33.

Downloaded from ClinicalKey.com at Ohio State University Libraries August 26, 2016.
For personal use only. No other uses without permission. Copyright ©2016. Elsevier Inc. All rights reserved.